

Dentofacial Considerations in Genioplasty

Majid Jamali, D.M.D.

ABSTRACT

Chin augmentation, particularly with implants, has become popular in recent years. For the most part, the focus is on the position of the pogonion. The rest of the mid-face, including the maxilla and mandible, are usually ignored. In this article, different scenarios and deformities in the maxillofacial complex that can affect the chin position and shape of its overlying soft tissue are illustrated. It is the author's view that a number of genioplasty augmentation procedures should be deferred. Discussion of alternative treatments should take place with patients regarding their underlying skeletal issues.

Facial profile enhancement is becoming increasingly common. In addition to the nose, the chin plays an important role in the overall esthetic appearance of the face; and chin augmentation has become an integral component of facial rejuvenation.

Genioplasty, primarily by means of implants, has become a popular procedure to enhance a receding chin. In younger patients, this procedure is typically performed during rhinoplasty to give harmonious balance to the face.⁵ In older patients, it is usually performed simultaneously with facial and neck rhytidectomy to give definition to the jaw line and improve the pre-jowl

sulcus. In this article, emphasis is placed on the importance of considering the whole face when evaluating the chin. Problems observed in the chin area could be, and usually are, a component of abnormalities of the maxilla-mandibular complex. These abnormalities may include such underlying issues as a divergent skeletal pattern, maxillary excess, short mandibular ramus, or condylar disease.

With proper diagnosis and treatment of chin abnormalities, the clinician and patient can be rewarded with superior results that are esthetically pleasing. Knowledge of osteology and muscle attachments, understanding and assessment of dental occlusion, as well as maxilla and mandibular anatomy and function, are all key to treatment planning, as these structures are all interrelated. Cephalometric analysis should be used to assist and to confirm the clinical findings. The clinician must be aware that true micrognathia, or a small chin, is rare.

Chin Origin and Significance

In human anatomy, the chin area, which is the lowest part of the face, is also known as the mental region (Figure 1). The chin evolved in the Middle and Late Pleistocene periods, anatomically distinguishing modern humans from their archaic counterparts.⁴ The origin of the chin and its biomechanical significance are somewhat controversial. As the chin allows for minute movements of the lips associated with speech, it is theorized that the chin evolved to uphold the jaw from the stresses associated with chewing and speech.¹ Because

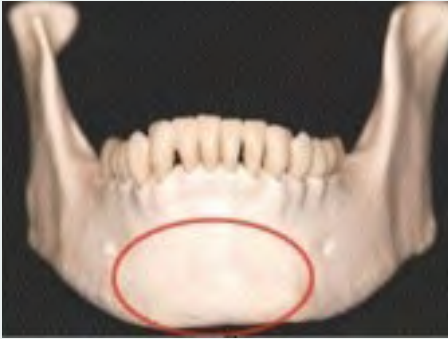

Figure 1. Position of chin, most anterior, inferior part of mandible.

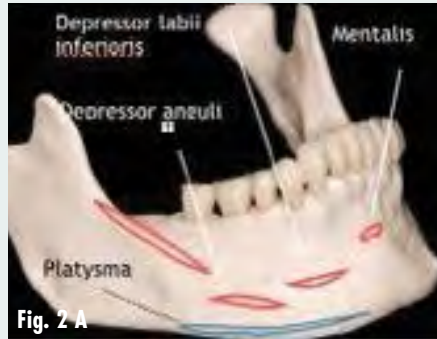



Fig. 2 A

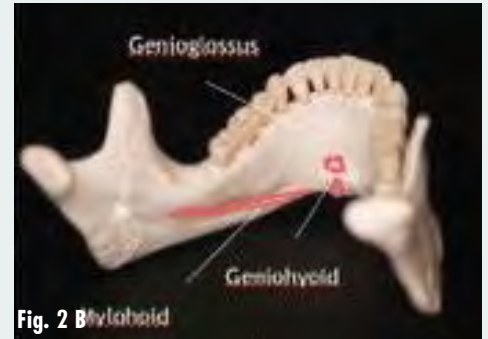

Fig. 2 B

Figures 2 A,B. Location of muscle attachments. (A) Note attachment location of depressor anguli oris and depressor labii inferioris on chin. (B) Because of location of these muscles, chin surgery alone would not completely improve large interlabial gap; therefore, jaw advancement or maxillary impaction would be necessary.



the chin differs in shape, depending upon gender, being more triangular in females and more square in males,² it has also been hypothesized that sexual selection played a part in its evolution.³

In many modern human cultures, a prominent chin is thought to represent a confident person.

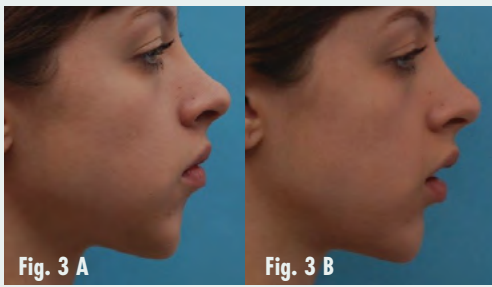Anatomy

Osteology

The chin has an external and internal surface. On the external surface, the ridge on the anterior midline is formed in utero by fusion of the mandible. This ridge divides inferiorly and surrounds the mental protuberance. On each side of the protuberance, slightly raised mental tubercles form. Proximal to the tubercles and inferior to the second premolar, the inferior alveolar nerve exits the mental foramen on each side.

Myology

Seven muscles attach to the chin. The muscles on the anterior surface include the mentalis, depressor labii inferioris, depressor anguli oris (partially) and platysma (Figure 2A). Mobilization of the lower lip is accomplished by these muscles. The geniohyoid, genioglossus and anterior belly of the digastric muscles arise from the posterior surface of chin (Figure 2B). These muscles oppose the downward pulling of the strap (infra-hyoid) muscles during speech and swallowing.



Figures 3 A, B. Taking proper photos. (A) Importance of evaluating patient with lips in repose (relaxed) can be appreciated from these photographs. Mentalis muscle restraining is frequently seen in patients with skeletal deformities. Lower lip is positioned in anterior and superior direction, flattening labiomental fold. (B) With lips in repose, interlabial gap usually widens and reveals occasionally normal-shaped labiomental fold.

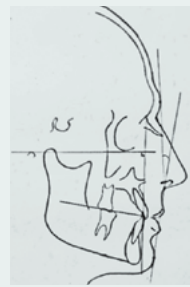


Figure 4. Cephalometric analysis for genioplasty. Upper facial (G-Sn) and lower facial planes (Sn-Po) form facial contour angle, which determines facial convexity that should be between -11 to -14 degrees. Patients with deficient chins will have obtuse angle. Those with prominent chins will have acute angle. Facial plane extends from the Nasion (N) to Pogonion (Po) and should be perpendicular to Frankfurt plane (FH). Antero-posterior position of chin in relation to upper face is determined here.

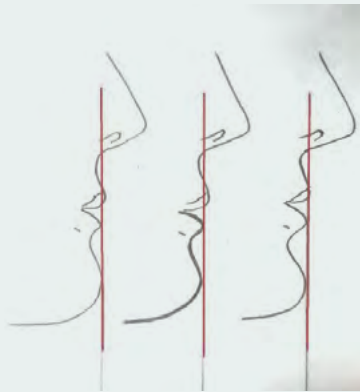
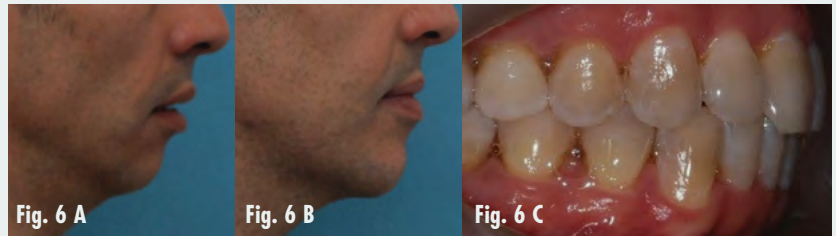

Figure 5. Shape is more important than position of chin. As demonstrated here, shape of soft-tissue drape is more important than anterior-posterior (AP) position of chin. Drawing in middle demonstrates gentle "S" curvature of labiomental fold. Note, pogonion on these patients are all in same AP position.



Figures 6 A-C. Maxillomandibular rotation, plus sliding genioplasty. (A) Preoperative photo of patient with moderate sleep apnea and Class I occlusion accomplished by orthodontic treatment (Invisalign). (B) Postoperative photo. (C) Dental occlusion maintained as Class I, pre- and postoperatively. Although patient could benefit cosmetically from chin augmentation, to obtain most advancement of the suprahyoid and tongue muscles, orthognathic surgery is preferred over chin augmentation alone.

Physical Evaluation

After eliciting a medical history and chief complaint, the expectations and degree of motivation of the patient should be evaluated. To create an appropriate treatment plan, radiographs (such as panoramic X-rays and cephalograms) and photographs are invaluable; it is highly recommended that they be obtained. Physical palpation of the mentum area for diagnosing the underlying problem is important but not sufficient. Once all of the data are gathered, it is the duty of the clinician to not only listen to the chief complaint but also to educate and guide the patient toward the proper treatment.

Clinical assessment begins with the patient's head in the Frankfurt horizontal, teeth in occlusion and lips in a relaxed position (i.e., in repose). The simple task of relaxing the mentalis musculature might be difficult for some patients. Many times, they have been subconsciously constricting these muscles for years in an attempt to appear normal (Figure 3). Therefore, if this is noticed, a few moments should be devoted to explaining and demonstrating proper relaxation of the lips and perioral musculature. A lateral cephalogram and photographs are subsequently obtained, with the lips in the same position.

When the above examination and diagnostic testing is completed, a sequential evaluation begins. Specific information that must be gathered when evaluating the chin includes the following:

- Mid-face appearance.
- Maxillary incisor show.
- Shape and appearance of the labiomental fold and soft tissue envelope.

- Dental occlusion.
- Position of the chin relative to the forehead.
- Shape of the chin.

Mid-face Appearance

From the profile view, the mid-face should appear round. Deficiencies in the anterior-posterior position of the maxilla result in a mid-face that appears flat and yields a mandible that appears pseudo-prognathic, making the labiomental fold obtuse.

Maxillary Incisor Show

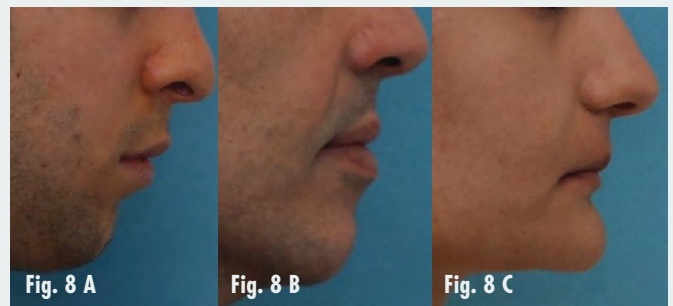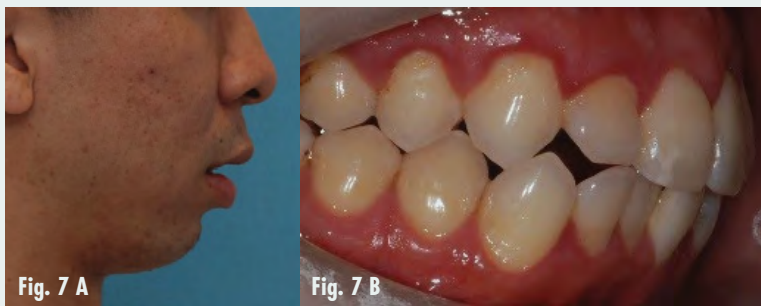The incisor show is a guide to assessing the vertical position of the maxilla. With a normal upper lip length at rest, 2 mm to 3 mm of incisors should be visible. Inadequate or excessive exposure of the incisors may represent vertical insufficiency or overgrowth of the maxilla. Influenced by the position and angulation of the maxilla, the mandible rotates around the condyles and dictates the final position of the pogonion of the chin.

Shape and Appearance of Labiomental Fold and Soft Tissue

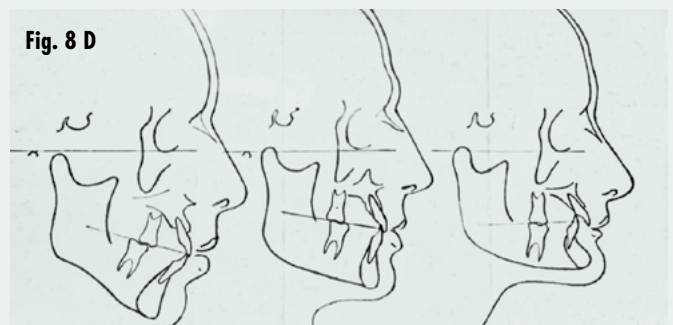
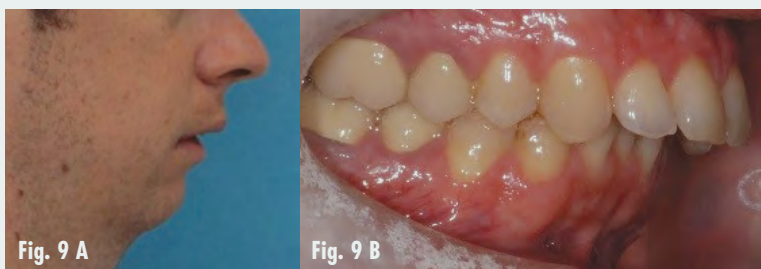
The labiomental fold should have a gentle S-shape curve. The vertical position and angulation of the upper and lower incisors, and the anterior-posterior position of the mandible, the maxilla and the chin itself, play a role in shaping this fold.

Dental Occlusion

The molar class relationship and the occlusal and incisal an-



Figures 8 A-D. Mandibular angle and its effect on chin shape and position. (A) High-angle occlusion. (B) Normal occlusion. (C) Low-angle occlusion. (D) Cephalometric drawings of patient.



Figures 9 A,B. Patient with Class II, Division 1, malocclusion. (A) Patient with retrognathic mandible. (B) Dental occlusion revealing proclined teeth and large overjet. Lips at repose usually show soft-tissue shape with deep fold overlying chin. Anterior-posterior position can be changed by chin augmentation, but this would sacrifice existing shape.

gles should be evaluated. These two angles are difficult to accurately assess clinically, emphasizing the importance of obtaining a lateral cephalogram. One must remember that finding a Class I occlusion does not rule out facial skeletal disharmony. Occasionally, a skeletal deformity might have been masked by previous orthodontic treatment. Although orthodontic camouflage can produce acceptable results in a mild dentofacial deformity, moderate and severe deformities can be left with devastating results, with poor soft-tissue profile. Hence, during clinical evaluation of the chin, one must be aware of past orthodontic treatment. For instance, a skeletal Class II (retrusive jaw) could present itself as a Class I dentally. Much like orthodontic treatment, a mild skeletal deformity can be corrected by genioplasty. However, moderate or severe deformities should have a well-formulated plan. In these situations, the teeth should be realigned to a proper angle and corrective jaw surgery should be performed. Only rarely could a genioplasty alone replicate the esthetic results and functionality produced by jaw surgery.

Position of Chin Relative to Forehead

Cephalometric analysis is used routinely to gauge the angular and linear relationships of the jaws and teeth to the cranium (Figure 4). It is a tool for planning treatment and for confirming clinical findings. When obtaining a cephalogram, the ra-

diation should be adjusted to allow the soft-tissue profile of the face to be evaluated, in addition to the bony structures. Similar to clinical evaluation and photography, the cephalogram should be obtained with the patient's teeth in occlusion and the lips in repose. A posterior-anterior cephalogram is useful in patients with asymmetry. Once the cephalogram is obtained, the analysis begins. There are several views regarding the proper position of the chin. A popular view suggests that the ideal position of the chin is where a vertical line perpendicular to the Frankfurt plane passes the vermilion of the lower lip and meets the pogonion (Figure 5). This analysis is ideal in a person with a Class I occlusion and properly angulated incisors. For instance, in Class II malocclusion, where the mandibular incisors are proclined, the lip is pushed forward by these teeth. As a result, the chin would appear posterior and micrognathia could be easily misdiagnosed as microgenia. Hence, the position of the lower lip alone should not be the deciding factor when determining the position of the chin.

Shape of Chin

The soft tissue drape overlying the mentum is esthetically more important than the position of the pogonion. The teeth and shape of the bone should give a gentle curvature to the soft tissue, making the labiomental fold appear as a gentle S-shaped curve.

Dentofacial Deformities and the Chin

Surgical and Orthodontic Considerations

A youthful, natural-looking face is supported by a well-balanced skeleton. The facial skeleton plays a major role in supporting the overlying soft tissue; therefore, when the skeleton is deficient, deep creases may form. As a result, aging can become more pronounced and occur at an earlier age, thereby requiring cosmetic procedures (such as fillers) to substitute for the skeletal deficiency.

Orthodontic treatment has been successful in creating optimal dental occlusion in patients who present with malocclusion. As discussed earlier, in mild skeletal deformities, good occlusion can camouflage the underlying facial deformities. Overlooking such signs as mid-face deficiency, a nasal dorsal hump, lack of nasal tip support, a large interlabial gap or a receding chin will result in suboptimal function and esthetics post-treatment. Young patients and their parents are usually satisfied with a masking procedure; however, many of these patients will be disappointed with their facial appearance when they reach adulthood.

In addition to poor esthetics, obstructive sleep apnea is an important condition that could result from retrognathia that has been untreated since an early age (Figures 6 A,B). The combination of sliding genioplasty and orthognathic surgery is a more effective treatment in sleep apnea patients than either surgery alone. Because most patients start their treatment by seeing an orthodontist, the responsibility rests with the orthodontist to educate patients about the necessity of surgery and the benefits of having it performed at a young age.

There are several types of dentofacial deformities that require treatment by means of orthodontics and orthognathic surgery instead of genioplasty alone. Some of the most common scenarios are discussed below. Many retrognathic patients tilt their chin upward to normalize the esthetics and open the posterior airway. Placement of the head in the Frankfurt horizontal position with the lips in repose will assist in diagnosing and treating a high-angle mandible. In these situations, rotation of the maxillomandibular complex will generally produce the best esthetics (Figure 7).

Occlusal Angle Abnormalities

The occlusal angle can cause major disharmony in the esthetics of the lower third of the face (Figure 8). A low occlusal angle may cause collapse of the lower third of the face and a protruding chin. A C-shape or concave face is usually observed in these patients; most will desire a smaller chin. By contrast, individuals with a large angle usually have a receding mandible or pseudo-microgenia. Examples can be seen in patients who present with condyle disorders or hemifacial microsomia. Guided by the amount of maxillary incisor tooth showing, maxillary and mandibular osteotomies are usually the best solutions to correct either a small or large occlusal angle.

Malocclusion

Class II

Division I: In this division, an increase in over-jet is seen, and the upper molars are anterior to the mesiobuccal groove of the lower molars (Figure 9). The anterior teeth are proclined, and the labiomental fold is acutely folded because of the upper incisors.

Division II: In this division, the molar relationship is the same as above, but the maxillary anterior teeth are retroclined. Usually a deep bite exists (Figure 10). With collapsed occlusion and a deep overbite, the posterior region of the mandible appears broad and the chin appears pointed and narrow. The chief complaint is usually the presence of a broad-shaped face and short, V-shaped chin. Advancing the mandible surgically increases the occlusal height and height of the lower third of the face, eliminating the need for genioplasty. Most patients with this condition would not be fully satisfied with genioplasty alone. Presurgical orthodontic treatment planning includes leveling the occlusion, with possible removal of teeth to decompensate for the proclined anterior mandibular teeth. Because the surgeon uses the new dental over-jet to advance the mandible and to place the pogonion in the correct position, esthetics are not sacrificed.

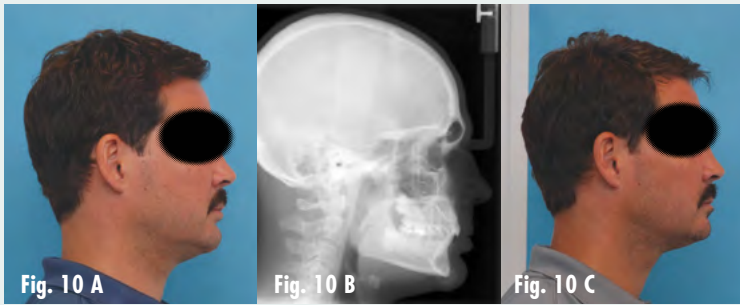
Class III

In this class, the upper molar is posterior to the lower molar's buccal groove. The over-jet is negative, and the lower incisors are in front of the upper incisors. The labiomental fold becomes flat, with a protruding mandible. Decompensation of the teeth and mandibular setback are ideal. In general, shaving of the protruding chin should be avoided.

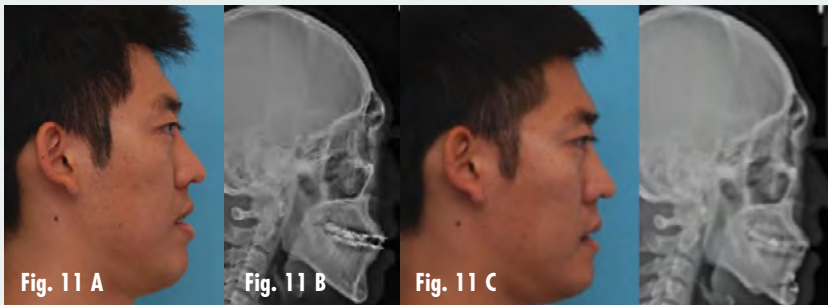
Vertical Maxillary Excess

Vertical maxillary excess (VME) causes the mandible to rotate around the condyles in a clockwise fashion (Figure 11). The pogonion, therefore, is placed in a posterior and inferior position, increasing the lower facial height and interlabial gap. Clinically, excessive exposure of maxillary incisors and a large interlabial gap will be seen. Genioplasty to close the interlabial gap is not completely successful. Proclining or intruding the incisors orthodontically may mask VME, but this orthodontic treatment is usually not stable. And it will not produce the best esthetic outcome in the mid-face region. Recently, the use of Botox has become popular for treating this condition. By paralyzing the perioral musculature, the lips become elongated and the gummy smile is hidden. However, this treatment inhibits all perioral musculature animation, so use of Botox in this region requires careful consideration.

The only treatment that can produce a multitude of beneficial effects is osteotomy. Superior positioning of the maxilla surgically can produce long-lasting, natural-appearing results. When surgery is chosen, orthodontic decompensation of the incisors to reveal the maxillary excess cannot be overemphasized. Only then



Figures 10 A-C. Patient with Class II deep bite. Patient initially wanted longer, lower face with protruding chin. (A) Photo showing deep fold, unattractive, “bulgy” chin as result of implant. Note already deep labiomental fold that implant worsened. Large chin implant had been placed below pogonion to accomplish this. Implant placed in presence of deep overbite, low occlusal plane and retrognathia will create unsightly, acute labiomental fold. If orthognathic surgery is deferred, sliding genioplasty with down-grafting can be performed to give more esthetically appealing soft-tissue chin. Bulginess of misplaced implant revealed submental scar. Patient’s main complaint was constant mild pain in area that often occurs with migration of chin implant. Erythema, which cannot be appreciated in preoperative photograph, disappeared few days after surgery. (B) Radiograph showing displaced implant below pogonion. (C) Gentler shape of chin postoperatively.



Figures 11 A-C. Patient presented with chief complaint of long chin. (A) Patient with maxillary excess. Large interlabial gap, midface deficiency can be appreciated. (B) Radiograph confirming clinical findings. In radiograph, note proclined maxillary teeth. Vertical maxillary excess was diagnosed, accompanied by large interlabial gap at repose. Orthognathic surgery was deferred by patient, as he only desired shorter chin. Wedge of bone was removed during osteotomy and segment was repositioned in anterior-superior direction. (C) Interlabial gap did not improve significantly after surgery; however, chin was shortened by 3 mm. Chin segment was anteriorly placed to recreate labiomental fold.

can the bony VME be truly appreciated and proper correction performed by superior positioning of the maxilla surgically. This procedure would restore the height of the lower face to a normal range, close the interlabial gap and remove excess gingival show. The condyles will be rotated and place the pogonion in a superior, anterior position, possibly eliminating the need for a genioplasty.

Anterior Open Bite

Similar to VME, anterior open bite will also result in a large interlabial gap. Most patients with an anterior open bite present with a Class II or Class III malocclusion. The shape of the chin and its position may be normal. Again, if the patient’s lips are not in repose during the examination, the labial fold would disappear, and the clinician might consider augmentation. Augmenting an otherwise normal chin would deepen the labiomental fold and produce highly unaesthetic results.

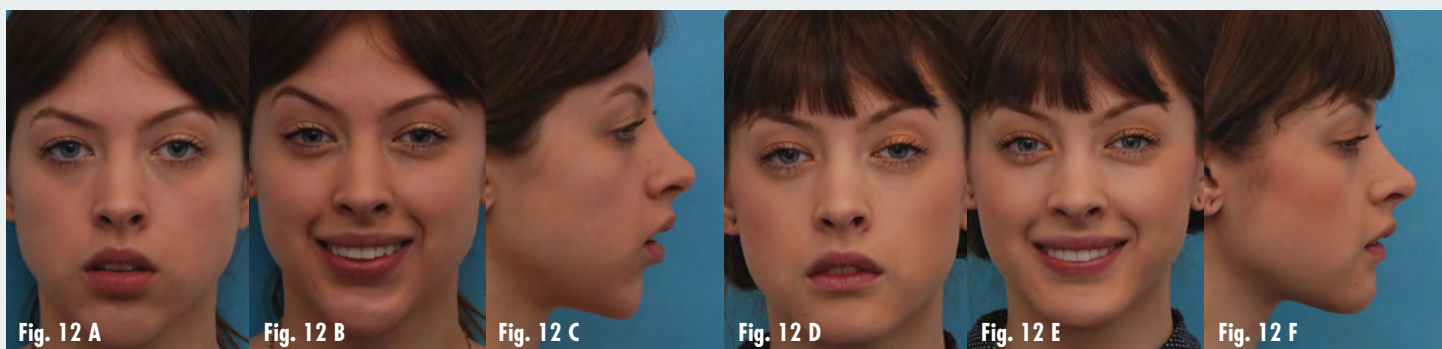
Mentoplasty

Sliding genioplasty and implants have been used frequently to augment a weak chin or enhance the effects of rhinoplasty. We suggest performing any chin or jaw surgery prior to rhinoplasty, because advancing these structures can make the nose appear smaller in an anterior-posterior direction. Recently, cosmetic fillers have become popular; however, they are temporary and the degree of augmentation is limited. Autografts have been tried in

the past, but they have become unpopular because of their relatively high morbidity.

With the advent of improved biomaterials, the use of implants has increased.^{6,7} Implants can be used to successfully augment soft or hard tissue. They have a high safety margin, and the insertion can be completed in minutes under local anesthesia. The types of alloplastic materials include mesh polymers, expanded polytetrafluoroethylene, polymethacrylate, polyethylene and silicone. Among these, solid silicone has gained in popularity because of its low toxicity and ease of placement and removal.⁸ After several months, a fibrous tissue capsule is formed around the implant. When placed incorrectly, implants can cause infection, and seromas and might migrate to the overlying dermal layer. Extended anatomic mandibular implants, which are available in four sizes, tend to migrate less than central implants. Bony resorption of up to 5 mm^{9,10} is commonly observed on radiographs, especially with larger implants.

The first transoral sliding genioplasty was described by Trauner and Obwegeser.¹¹ Sliding genioplasty is a simple and effective procedure. One of its most useful advantages is the ease with which it can be moved. When the osteotomy is completed, the segment can be moved or reshaped in any direction the clinician wants. Conversely, an implant cannot increase the vertical height and should not be placed in the inferior section of the mandible. Implants placed in this area may cause discomfort, since the over-



Figures 12 A-F. Chin implant migration below pogonion resulted in elongation of chin and face, resulting in V-shaped appearance. (A) Note V-shaped face preoperatively. (B) Unnatural look to chin with irregular folds and wrinkles. (C) Increase in vertical height, as well as improper shape of labiomental fold is seen. (D, E, F) By removal of mal-positioned implant and performing sliding genioplasty with advancement, shape and position of chin is recreated. Patient's other complaint was presence of wrinkling over chin when she smiled or was at rest. This is surgical wound closure issue, which can be corrected by re-approximating mentalis muscle into its initial position.

lying platysma is a thin muscle. No matter which technique is used, the augmented chin should exhibit a smooth transition to the body of the mandible without producing a bulbous appearance.

Revision Genioplasty

As the number of genioplasties has increased, so has the number of revision surgeries. Dissatisfaction with the initial procedure, which may not have satisfied a more severe dentofacial deformity, will often lead patients to seek a revision genioplasty. With moderate dentofacial deformities, edema in the early postoperative period plays a major role in masking the deficiencies. However, over time, many of these patients will seek removal of their implant and request other treatment options. With malpositioned and/or migrated implants, the symptoms and signs include erythema, pain and soft-tissue changes (Figure 12). Submental displacement of the implant can occasionally lead to the implant breaking through the soft tissue because the thin muscle layer in the area provides little soft-tissue coverage and support.

If the chin implant is removed for whatever reason, insertion of another implant or a sliding genioplasty should be performed. This will prevent collapse of the fibrous capsule and maintain the soft-tissue projection. The goal is to recreate the gentle curvature of the soft-tissue drape.

Conclusion

Genioplasty is a relatively simple and short procedure. Although it is a minor procedure, the diagnostic process prior to contemplating surgery can be challenging, especially when the surgeon seeks high-quality results. Successful genioplasty begins with the surgeon's artistic and scientific understanding of the relationships between the mentum and other facial structures.

During examination, the clinician must consider all the deformities that are related to the chin position and shape,

including the posterior airway space. Sliding genioplasty is recommended over other methods because of its versatility and esthetically natural results. Again, although many genioplasties are currently performed, true microgenia remains a rare condition. //

Queries about this article can be sent to Dr. Jamali at Drjamalioms@gmail.com.

REFERENCES

1. Ichim I, Kieser J, Swain M. Tongue contractions during speech may have led to the development of the bony geometry of the chin following the evolution of human language: a mechanobiological hypothesis for the development of the human chin. *Medical Hypotheses* 2007;69 (1): 20-24. doi:10.1016/j.mehy.2006.11.048.
2. O'Loughlin MM, Dean V. *Human Anatomy*. Boston: McGraw-Hill Higher Education. 2006, pp. 400-401. ISBN 0072495855.
3. Thayer ZM, Dobson SD. Sexual dimorphism in chin shape: implications for adaptive hypotheses. *Amer J Physical Anthropology* 2010;143 (3):417-425. doi: 10.1002/ajpa.21330.
4. Daegling DJ. Functional morphology of the human chin. *Evolutionary Anthropology: Issues, News, and Reviews* 1993;1(5):170-177. doi:10.1002/evan.1360010506.
5. Davis PKB. Chin augmentation with rhinoplasty: a tutorial dissertation. *Br J Plast Surg* 1983;36:204-209.
6. Beekhuis GJ. Augmentation mentoplasty with polyamide mesh. *Arch Otolaryngol* 1984;100:364-367.
7. Silver WE. Chin and molar augmentation. *Head and Neck Surg. Otolaryngol*. Philadelphia: Lippincott Co. 1993, 2284-2298.
8. Scaccia FJ, Allphin AL, Stepnick DW. Complications of augmentation mentoplast: a review of 11095 cases. *Int J. Aest Restorative Surg* 1993;1:3-8.
9. Robinson M, Shuken R. Bone resorption under plastic chin implants. *J Oral Surg* 1969;27:116-118.
10. Robinson M, et al. Bone resorption under plastic chin implants. Follow-up of a preliminary report. *J Oral Surg* 1969;27(2):116-118.
11. Trauner R, Obwegeser H. Surgical correction of mandibular prognathism and retrognathism with consideration of genioplasty. *Oral Surg* 1957;10:677.



Majid Jamali, D.M.D., is an oral and maxillofacial surgeon practicing in New York City.